

Musculoskeletal Imaging * Review

ABSTRACT

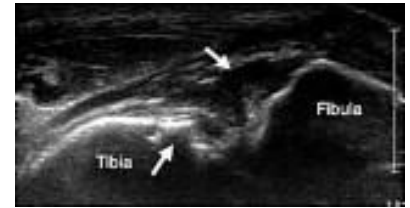
Ultrasound vs MRI.

The development of less expensive portable ultrasound machines has opened the market to non-radiologists, while applications for musculoskeletal ultrasound have broadened.

It is said that selective substitution of musculoskeletal ultrasound for MRI could result in significant cost saving to the health care system.

But, is it that simple? What about important issues such as accuracy, variability, education, and competence?

This course addresses these issues and also compares and contrasts image interpretation, accuracy, observer-variability, economic impact, and education with regard to musculoskeletal ultrasound and MRI.



Keywords: health care policy, imaging utilization, medical education, MRI, musculoskeletal ultrasound, radiology residency

FOCUSED IMPACT ON MRI

OBJECTIVE

This article will compare and contrast image interpretation, accuracy, observer variability, economic impact, and education with regard to musculoskeletal ultrasound and MRI because these factors will influence the growth of musculoskeletal ultrasound and the impact on MRI.

CONCLUSION

The use of musculoskeletal ultrasound continues to grow and there are a number of factors that impact MRI. The development of less expensive portable ultrasound machines has opened the market to non-radiologists, and applications for musculoskeletal ultrasound have broadened. Selective substitution of musculoskeletal

ultrasound for MRI can result in significant cost saving to the health care system. Although this change could decrease the use of MRI, issues related to accuracy, variability, education, and competence must be addressed.

There have been a number of significant advances in musculoskeletal ultrasound since its early use in in the evaluation rotator cuff that have impacted its utilization. In 1977, Mayer ^[1] showed rotator cuff abnormalities with ultrasound in an exhibit at the annual convention of the American Institute of Ultrasound in Medicine (AIUM) in Dallas, TX. Since 1977, technology has markedly improved ultrasound imaging. Transducers used to evaluate the rotator cuff are now 10MHz or greater, and transducers are available at frequencies greater than 15 MHz that are commonly used to evaluate superficial structures.

Musculoskeletal Imaging * Review

These high-frequency transducers allow visualization of superficial structures with resolutions approaching 200 μ m, greater than routine MRI [2]. Small structures can now be easily identified and their abnormalities can be diagnosed with confidence. Improved resolution also allows visualization of tendon infrastructure and individual peripheral nerve fascicles [3]. Ultrasound evaluation for peripheral nerve abnormalities, such as nerve entrapment disorders and nerve dislocation, is now common at many institutions as part of musculoskeletal imaging [4].

Because of these technologic advances, ultrasound can now be considered an important diagnostic tool alongside MRI for imaging the musculoskeletal system. Although of care for imaging ligament, cartilage, and interosseous abnormalities. However, ultrasound is an ideal and inexpensive alternative for imaging superficial structures, such as the tendons, ligaments, and peripheral nerves of the distal extremities as well as for evaluation for soft-tissue foreign bodies.

In addition to improvements in transducer technology, another change that has dramatically impacted utilization of musculoskeletal ultrasound is the development of compact ultrasound machines, most of which are available at less cost than conventional cart-based machines. New compact machines are typically the size of a notebook computer. With these advances, the ultrasound machine can be brought to the

patient—for example, into the procedure room, emergency department, or clinic. In combination with the relatively reduced prices of these portable machines compared with conventional ultrasound machines, this portability has created a new market for musculoskeletal ultrasound beyond those specialized in imaging in the traditional sense.

The changes in ultrasound technology resulting in improved resolution, decreased machine size, and decreased price have impacted the utilization of musculoskeletal ultrasound with potential indirect effects on MRI utilization. For example, if the rotator cuff is primarily evaluated with ultrasound, then utilization of MRI could decrease. Although those in the radiology community in the United States have been relatively slow to embrace musculoskeletal ultrasound, many subspecialties are eager to use ultrasound in their daily practice to improve patient care. The number of musculoskeletal ultrasound studies increased 200% from 1996 to 2006, but this growth was most significant in specialties outside the radiology profession (Nazarian LN, presented at the 2008 annual meeting of the Radiological Society of North America [RSNA]). According to Medicare data, the use of musculoskeletal ultrasound by radiologists increased 42% from 1996 to 2006; however, there was disproportionate growth among other specialties, including podiatry, which showed a 12,025% increase in utilization over that same time period (Nazarian LN, 2008 RSNA meeting). As a result, less than 50% of musculoskeletal ultrasound in 2006 was

Musculoskeletal Imaging * Review

performed by a radiologist (Nazarian LN, 2008 RSNA meeting). Increased utilization of musculoskeletal ultrasound by other groups could decrease the number of both ultrasound and MRI studies interpreted by radiologists. It is inevitable that this expanding use of ultrasound for musculoskeletal imaging will impact the utilization of MRI. It is therefore important to address the pros and cons of musculoskeletal ultrasound compared with MRI. This article will compare and contrast image interpretation, accuracy, observer variability, economic impact, and education with regard to musculoskeletal ultrasound and MRI because these factors will influence the growth of musculoskeletal ultrasound and the impact on MRI utilization.

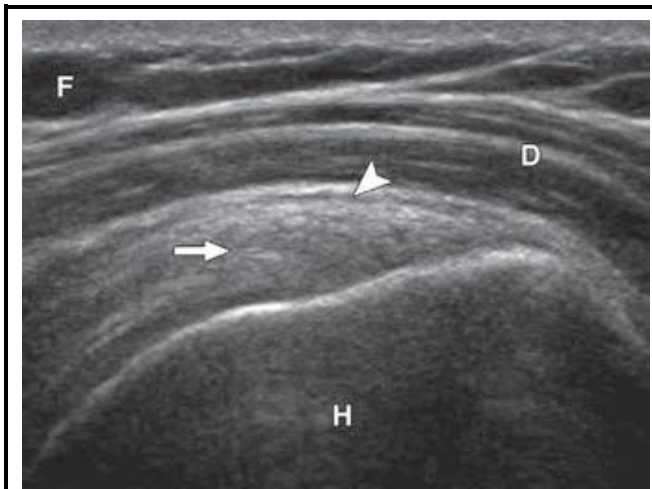


Fig.1. 30-year-old woman with normal shoulder. Ultrasound image of supraspinatus tendon (long axis) shows normal hyper echoic and fibrillar supraspinatus (arrow).

Note deltoid muscle (D), humerus (H), subcutaneous fat (F), and collapsed subacromial-subdeltoid bursa (arrowhead).

IMAGE INTERPRETATION

Similar to MRI, ultrasound is capable of showing the anatomy of the musculoskeletal system, including tendons, muscle, ligaments, and fluid [2, 5]. One

limitation of ultrasound is the inability of the ultrasound beam to penetrate beyond bone cortex. Although ultrasound can evaluate some aspects of joint cartilage, MRI offers a more comprehensive evaluation of those structures. The same is true for other intra-articular structures, such as the cruciate ligaments in the knee where MRI is considered the imaging test of choice. Nonetheless, much of the musculoskeletal system can be evaluated with ultrasound.

On ultrasound, normal tendons appear hyper-echoic with a fibrillar echo texture [2, 6] (Fig. 1). When the ultrasound beam is perpendicular to a tendon, numerous intratendinous echogenic interfaces between collagen bundles and endotendineum septa result in the fibrillar appearance, which can be seen in both the short axis and long axis to the imaged tendon [6]. When imaging tendons with ultrasound, it is important to maintain the ultrasound beam perpendicular to the tendon fibers because angulation as little as 5° in the long axis or 2° in the short axis will cause the tendon to appear artifactually hypo echoic due to anisotropy [7]. It is essential for the individual performing ultrasound to continually direct the ultrasound beam so that any hypo echoic segment of tendon is imaged perpendicular to eliminate anisotropy.

On ultrasound, muscle tissue appears predominately Hypo-echoic with interspersed Hyper echoic septations [8] (Fig. 1). This appearance is produced by muscle fibers grouped together to form fascicles, which are visible at ultrasound as hypo echoic bundles separated by the echogenic fibro adipose perimysium septa [2]. When imaging in the short axis, muscle tissue produces a "starry sky" appearance. Normal ligaments appear hyper echoic with a compact

Musculoskeletal Imaging * Review

fibrillar echo texture at ultrasound ^[2, 9] (Fig. 2A). This compact appearance and the direct attachment from bone to bone allow differentiation of ligaments from tendon. Similar to tendons, ligaments show anisotropy when not imaged perpendicular to the ultrasound beam ^[2]. With regard to the peripheral nerves, ultrasound shows the individual nerve fascicles as hypo-echoic ^[3] (Figs. 2B and 2C). The surrounding connective tissue stroma or perineurium appears hyper-echoic, so a striated appearance is seen when imaging a peripheral nerve in the long axis ^[2]. When imaging in the short axis, a peripheral nerve has a honeycomb appearance where each nerve fascicle appears hypo-echoic with surrounding hyper-echoic connective tissue elements ^[2]. Other structures shown by ultrasound include the surface of bone, which appears smooth and hyper-echoic ^[2] (Fig. 1). Fibrocartilage at ultrasound appears hyper-echoic, whereas hyaline articular cartilage at ultrasound is hypo-echoic and nearly anechoic ^[2]. Subcutaneous fat on ultrasound is variable and heterogeneous because pure fat is hypo-echoic and fibro-fatty tissue has internal reflective echoes.

ACCURACY

Comparing the accuracy of musculoskeletal ultrasound with that of MRI is difficult because the results depend on the individual who is acquiring the images and his or her level of experience. The goal of any imaging method is to produce standardized and reproducible imaging planes either relative to an extremity or to a particular structure, which allows accurate image

interpretation. With proper training, this is possible with ultrasound similar to training an MRI technologist to produce standardized imaging planes; ineffective training of the individual performing ultrasound will result in inadequate imaging planes and inaccurate image interpretation. Other factors that make assessment of accuracies difficult include variable study designs, variable gold standards, and variable equipment. For example, such factors have resulted in quoted sensitivities for the diagnosis of rotator cuff tear that range from 33% to 100% ^[5]. Regardless, it is known that high accuracies can be obtained with the proper training and standardized technique using appropriate equipment (Table 1).

Most data on musculoskeletal ultrasound accuracy are from studies of the rotator cuff because evaluation of the shoulder is the most common use of ultrasound in most practices. Early reported accuracies with ultrasound should be disregarded because these data were acquired from ultrasound machines with lower resolution compared with current transducers. However, several more recent studies have compared ultrasound with surgery with regard to the diagnosis of rotator cuff tears. In their 2000 study, Teefey et al. ^[10] showed in 100 consecutive shoulders with arthroscopic surgery confirmation that ultrasound was able to diagnose full-thickness rotator cuff tears with a 96%. With regard to the detection of partial thickness tears, an accuracy of 94% has been reported using ultrasound ^[11]. MRI has similar accuracies of 92–97% for full-thickness rotator

Musculoskeletal Imaging * Review

cuff tears ^[12] and an accuracy of 92% for partial-thickness tears ^[13]. Both ultrasound and MRI have also been shown to be of comparable accuracy for the identification and measurement of the size of rotator cuff tears ^[14]. Investigators have also assessed accuracies in the diagnosis of ultrasound for the diagnosis of ankle tendon abnormalities. Rockett et al. ^[15] reported an accuracy of 94% when ultrasound was used to diagnose tendon tears of the ankle. Evaluating specific ankle tendons with ultrasound, studies have shown 90% accuracy in the diagnosis of peroneal tendon tears ^[16] and 92% accuracy in differentiating full-thickness from partial-thickness Achilles tendon tears ^[17]. MRI has also shown high accuracies in the diagnosis of ankle tendon tears, with an accuracy of 96% reported for MRI diagnosis of tibialis posterior tendon tear ^[18]. Another study of tibialis posterior tendon pathology with clinical correlation showed that ultrasound and MRI findings were concordant in most cases ^[19].

With regard to the anterior talofibular ligament, ultrasound was able to diagnose a ligament tear with 100% accuracy proven at surgery ^[20]. A similar study showed that MRI can diagnose anterior talofibular ligament tears with 94% accuracy ^[21]. With the addition of intra-articular contrast material, an accuracy of 100% has been reported in the diagnosis of anterior talofibular ligament tear using MR arthrography ^[22].

Although many of the studies are somewhat limited because of small sample size, the results over the years show that ultrasound can be an

alternative to MRI in the evaluation of many musculoskeletal abnormalities. Studies have shown ultrasound to be accurate in the diagnosis of conditions that require joint movement or positioning to display the abnormality, such as peroneal tendon subluxation in the ankle (100% positive predictive value) ^[23]. Such diagnoses are not possible or are difficult with routine MRI.

OBSERVER VARIABILITY

Intrinsic to musculoskeletal ultrasound accuracy is the issue of observer variability. With ultrasound, this variability is influenced at several levels. First, proper equipment including transducer selection is required to optimize results. Next, the individual performing ultrasound must understand anatomy to find the structure of interest, adequately evaluate that structure in a standardized imaging plane, recognize artifacts such as anisotropy and correct for them, recognize abnormalities and adequately image, and finally interpret the imaging findings. With MRI, assuming that the MRI technologist is trained to obtain the proper imaging plane and sequence, variability is primarily at image interpretation. Minimizing variability depends on proper training, which is common to both ultrasound and MRI. Several studies have addressed the issue of observer variability with musculoskeletal ultrasound. O'Connor et al. ^[24] assessed the abilities of three observers, two with more than 6 years and the third with 6 months of experience, in the evaluation of patients with a painful shoulder. In their series of 24 consecutive patients, they found poor agreement with a kappa value of

Musculoskeletal Imaging * Review

0.18–0.21 between the one inexperienced observer and the two experienced observers. Middleton et al. [25] evaluated the rotator cuff in 61 patients with two observers, both with more than 5 years of experience, and reported 80% agreement.

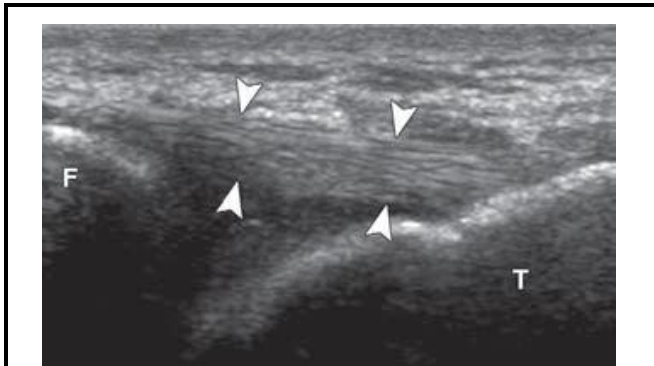


Fig.2 44-year-old man in excellent health and normal sonographic anatomy.

A
 Ultrasound image of anterior talofibular ligament (long axis) shows compact, hyper-echoic, and fibrillar ligament (*arrowheads*). F = fibula, T = talus.

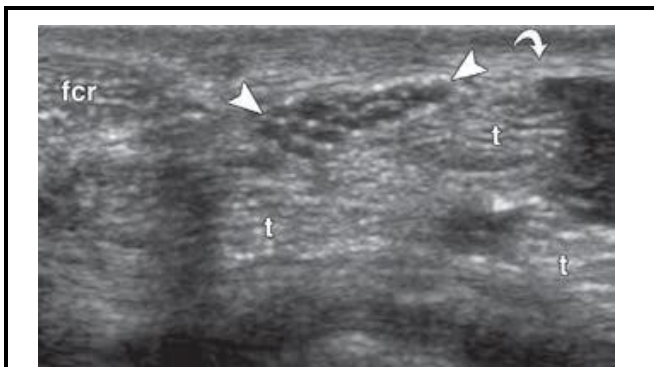


Fig.2 44-year-old man in excellent health and normal sonographic anatomy

B
 Ultrasound image of median nerve (short axis) (*arrowheads*) shows hypo-echoic nerve fascicles surrounded by hyper-echoic connective tissue. Note flexor carpi radialis tendon (fcr), flexor digitorum tendons (t), and flexor retinaculum (*arrow*).

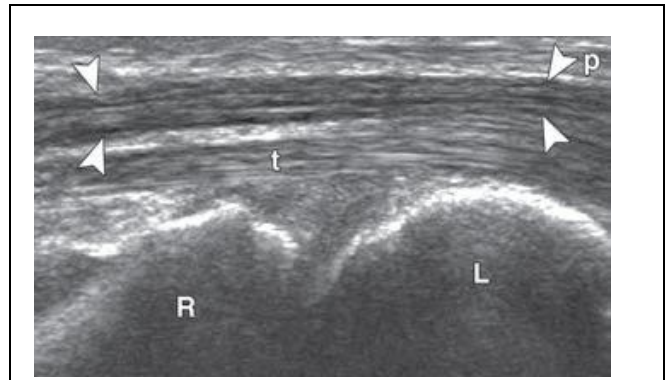


Fig.2 44-year-old man in excellent health and normal sonographic anatomy

C
 Ultrasound image of median nerve (long axis) shows hypo-echoic nerve fascicles (*arrowheads*). t = flexor digitorum tendon, p = palmaris longus tendon, R = radius, L = lunate.

Another study compared one observer with 6 months of experience and another with 15 years of experience in evaluation of the shoulder and found very good agreement for full-thickness rotator cuff tears ($\kappa = 0.90$) and moderate agreement for partial-thickness ($\kappa = 0.63$) and intratendinous ($\kappa = 0.57$) tears [26]. A study evaluating the patellar tendon had two observers with a total of more than 20 years of experience and reported 100% agreement [27]. One can conclude from these studies that interobserver variability is dependent on years of experience. Although the experience of the observer can be estimated by the number of years, integral to this issue is the number of cases per year and, of course, the quality of training. Last, one study from Europe evaluated interobserver variability of experienced rheumatologists and a radiologist in evaluation of patients from a rheumatology clinic and reported kappa values of 0.5 for the shoulder; 0.54 for the ankle and foot; and 0.6 for the wrist, hand, and knee, which overall are considered good interobserver variability [28].

Musculoskeletal Imaging * Review

TABLE 1: ACCURACY OF ULTRASOUND VERSUS MRI

Imaging Diagnosis	Accuracy (%) [Reference no.]	
	Ultrasound	MRI
ROTATOR CUFF TEARS		
Full thickness	96 [10]	92-97 [12]
Partial thickness	94 [11]	92 [13]
ANKLE TENDON TEARS		
Peroneal tendon	94 [15]	
	90 [16]	
Achilles tendon	92 [17]	
Tibialis posterior tendon		96 [18]
ANTERIOR TALOFIBULAR LIGAMENT TEAR	100 [20]	94 [21]

Observer variability does exist with MRI as well. With regard to MRI of the rotator cuff, Robertson et al. [29] reported overall moderate interobserver agreement and moderate to good intraobserver agreement between four observers. They found good to excellent agreement between readers in the diagnosis of full-thickness tendon tears but poor agreement in the diagnosis of partial thickness tears.

ECONOMICS

The economic implications of musculoskeletal ultrasound versus MRI have both local and national effects related to reimbursement. For a diagnostic ultrasound of an extremity (nonvascular, real time with image documentation: current procedural terminology [CPT] code 76880), the Medicare physician fee schedule payment is approximately \$101.00 for the technical fee and \$31.00 for the professional fee [30]. For MRI of an upper extremity joint without contrast (CPT code 73221), the Medicare physician fee schedule payment is approximately \$371.00 for the technical fee and \$73.00 for the

professional fee [30]. Simply looking only at the professional fee, one can see that for musculoskeletal ultrasound to compete financially one must interpret at least two extremity ultrasounds in the time to interpret an MRI. This can only be realistically accomplished if images are acquired by a diagnostic medical sonographer and presented to the radiologist, similar to acquiring ultrasound images of other organ systems. The average relative value unit (RVU) for an extremity ultrasound is 0.59 compared with an RVU of 1.62 for an extremity MRI study without contrast, again suggesting that one should be able to interpret two to three extremity ultrasound studies in the time to interpret one MRI study of the extremity [31]. Utilization of ultrasound and MRI also has a significant effect at a national level. A study by Parker et al. [32] evaluated utilization of musculoskeletal MRI at their institution over a 1-year period with regard to the indication for each study. They found that approximately 45% of primary musculoskeletal diagnoses and 31% of all musculoskeletal diagnoses made with MRI could have been made with the use of ultrasound. Based on this information, they concluded that appropriate substitution of ultrasound for MRI would result in at least \$6.9 billion in savings from 2006 to 2020 [32]. Given the continued increase in diagnostic imaging usage and costs, study results such as these may affect health care reform decisions. Ideally, ultrasound will have a role in the evaluation of the musculoskeletal system that complements MRI, with the optimal imaging test selected on the basis of clinical findings.

Musculoskeletal Imaging * Review

EDUCATION

Vital to the success of musculoskeletal ultrasound and maintaining a high standard of practice is education. Questions to be addressed include the following: When should musculoskeletal ultrasound be taught, who should teach it, who should learn it, and how do we assess competence? Rao et al. [33] evaluated the benefit of ultrasound when introduced during the first year of medical school.

This pilot study showed that 83% of students agreed or strongly agreed that the experience was positive and 91% agreed there would be benefit from continued ultrasound education.

With regard to diagnostic radiology residency programs, residents are typically exposed to many aspects of musculoskeletal imaging, including MRI and radiography; however, exposure to musculoskeletal ultrasound is relatively limited. Many times the use of musculoskeletal ultrasound is limited to guidance of percutaneous procedures, such as biopsies and joint or abscess aspiration.

Currently, there is relatively limited musculoskeletal ultrasound testing by the American Board of Radiology (ABR) compared with MRI. This can be viewed as an accurate reflection of current radiology resident program curriculums, or perhaps a lack of emphasis of musculoskeletal ultrasound on the board examinations could cause a lack of interest in the residency program. Musculoskeletal ultrasound may also be taught during a musculoskeletal radiology fellowship, which is a 1-year program

after completion of a 4-year radiology residency. Berquist et al. [34] assessed trends in postgraduate musculoskeletal fellowship programs in the United States in 2003 and found that 100% of musculoskeletal fellowship programs included extremity MRI training in comparison with 60% providing training in musculoskeletal ultrasound, both diagnostic and interventional. For comparison, this study also showed that 71% of the programs provided training in spine MRI and 58% provided training in spine intervention. In 2006, the members of the Society of Skeletal Radiology were surveyed to assess their attitudes about musculoskeletal ultrasound as well as the current and future status of musculoskeletal ultrasound. The results showed that 55% of those surveyed use musculoskeletal ultrasound for diagnostic purposes. The members also believed that radiology residency training does not adequately include musculoskeletal ultrasound, whereas musculoskeletal fellowship training does include adequate training (Kransdorf MJ, 2008 RSNA meeting).

It was interesting that those surveyed also believe that musculoskeletal ultrasound should not be part of the ABR examination, possibly a reflection of the inadequate musculoskeletal ultrasound training provided in the residency program. Another difficult topic pertains to who should perform musculoskeletal ultrasound. One perspective is that radiologists should perform musculoskeletal ultrasound given their years of training in imaging and broad knowledge of the various imaging techniques [35]. A further

Musculoskeletal Imaging * Review

argument is that radiologists act as gatekeepers for imaging, which would help guide appropriate imaging and avoid the excessive costs related to self-referral. One study has shown that physicians who do not refer patients to radiologists but rather perform imaging as part of their practice order 4–4.5 times more imaging examinations [35]. Information such as this will not likely go unnoticed in the setting health care reform. The other perspective is that ultrasound imaging performed by clinicians can be focused and can immediately impact patient care. Education then becomes the issue because adequate training of non-radiologists is challenging; for comparison, musculoskeletal radiology training requires a 1-year fellowship beyond a dedicated 4-year diagnostic radiology residency. Integration of musculoskeletal ultrasound with other musculoskeletal imaging, such as MRI, CT, radiography, and interventional procedures, as part of a musculoskeletal fellowship has significant advantages. Regardless, it is important that the high standards in musculoskeletal imaging do not decrease if other specialties have ineffective training programs and suboptimal practice guidelines. One must not forget about the important role of the diagnostic medical sonographer for workflow efficiency, although a mechanism to provide adequate musculoskeletal ultrasound training to this group has difficulties as well. Nonetheless, the physician must be competent in musculoskeletal ultrasound, especially when the diagnostic medical sonographer is training because there is need for support, feedback, and continued education.

Establishing competence in ultrasound is a difficult task. Testing is one manner to prove competence, and MRI is effectively tested on the ABR examinations; however, there is relatively much less musculoskeletal ultrasound as part of these examinations. In addition, competency in musculoskeletal ultrasound not only includes image interpretation but also scanning technique because this directly affects image interpretation. Because there is no currently effective testing method to evaluate musculoskeletal ultrasound, many people have looked at the number of ultrasound examinations completed as part of a training program to assess competency. Hertzberg et al. [36] evaluated first-year radiology residents who were in their general ultrasound rotation by testing their competence with ultrasound after increments of 50 cases. They found that significant errors persisted even after 200 cases, with a passing rate of only 16% and concluded that 200 cases is not a sufficient number for adequate training.

Another study showed that even when ultrasound was integrated into a 1-year academic musculoskeletal radiology fellowship, at least 50 shoulder ultrasound examinations were needed; there was significant variability suggesting that more than 50 cases were needed (Jacobson JA, et al., presented at the 2008 annual meeting of the Society of Skeletal Radiology).

To address the issue of competence, the AIUM has established practice guidelines for musculoskeletal ultrasound [37], with the goal of providing uniform guidelines of high standards.

Musculoskeletal Imaging * Review

Practice accreditation is an additional step to ensure high standards of an ultrasound practice.

APPLICATIONS

When comparing ultrasound and MRI, there are many applications common to both imaging methods [38, 39]. Most of these applications include evaluation of superficial structures, such as tendon and ligament abnormalities (Figs. 3 and 4). The choice between ultrasound and MRI in such evaluations is determined by availability, referring physician preference, and the experience of the radiologist because in many settings accuracies can be similar. Patient choice is also important because it has been shown that most patients with a painful shoulder prefer ultrasound over MRI [40]. Compared with ultrasound, MRI offers a more comprehensive evaluation that includes intra-articular structures, bone marrow, and deep soft tissues; however, there are several applications in which ultrasound may complement MRI and may even have advantages over MRI^[41]. These applications are not limited to but include evaluation of peripheral nerves, evaluation for soft-tissue foreign bodies, evaluation of soft-tissue abnormalities adjacent to hardware, and evaluation of abnormalities that require specific extremity movement or positioning to provide a diagnosis.

Although MRI has been proven effective in the evaluation of peripheral nerves, the advantages of ultrasound relate to the higher resolution of ultrasound, its ability to efficiently image an entire extremity, and the benefit of patient

feedback. When imaged in the short axis, peripheral nerves have a characteristic appearance that allows easy identification^[3] (Fig. 2B). Once identified, the peripheral nerve can be easily evaluated proximally and distally throughout its course.

A nerve that is abnormally hypo-echoic and swollen at a potential site of entrapment indicates an entrapment neuropathy^[4]. Typically direct compression of the nerve at the entrapment site with the ultrasound transducer elicits symptoms. The addition of dynamic imaging also allows the diagnosis of specific peripheral nerve abnormalities, such as diagnosis of ulnar nerve dislocation at the elbow with elbow flexion^[42] (Fig. 5) and diagnosis of Morton neuroma with medial and lateral manual compression of the foot, causing the neuroma to displace in a plantar direction and to produce symptoms (the sonographic Mulder sign)^[43].

With regard to the evaluation of soft-tissue foreign bodies, ultrasound has the advantage of high resolution that allows identification of foreign bodies as small as 0.5 mm^[44]. Investigators have shown that wooden foreign bodies as small as 2.5 mm can be identified in the soft tissues by ultrasound with 92% accuracy in a cadaver model [45]. All soft-tissue foreign bodies are initially hyper-echoic^[46] (Fig. 6). Often a hypo-echoic halo with increased flow on color or power Doppler imaging from inflammation surrounds the foreign body increasing its conspicuity^[47].

Musculoskeletal Imaging * Review

Artifact deep to the foreign body is related to its surface attributes. A smooth flat surface will cause reverberation and an irregular surface will cause shadowing; often foreign bodies will display both artifacts [46]. Ultrasound can localize the foreign body, identify complications such as septic tenosynovitis and abscess, and then be used to mark the skin assisting surgical removal [48].

Another effective ultrasound application is evaluation for a soft-tissue abnormality near metal hardware [49] (Fig. 7). Although significant advances have been made with CT and MRI with regard to suppression of metal artifact [50], evaluation with ultrasound is ideal in that the artifact from metal is deep to the hardware without obscuring the adjacent soft tissues. One example of this application is in the setting of infection, where fluid and abscess can easily be identified superficial to a metal plate. Another example is evaluation of soft tissues, such as tendon, immediately adjacent to a metal screw or plate. As with all musculoskeletal applications, evaluation becomes more limited with deeper structures as resolution decreases.

With regard to dynamic imaging, ultrasound has significant advantages over MRI [51]. There are several examples in which an extremity must be positioned or actively moved to show an abnormality. In the shoulder, this includes external rotation of the shoulder in evaluation for biceps brachii tendon dislocation [52], arm elevation in evaluation for impingement and adhesive capsulitis

[53], and hand crossover in evaluation for acromioclavicular joint subluxation [54].

In the elbow, examples include elbow flexion for diagnosis of ulnar nerve dislocation and snapping triceps syndrome [42] (Fig. 5) and valgus stress for evaluation for an ulnar collateral ligament tear [55, 56] (Fig. 8). In the finger, flexion is used to diagnose extensor hood injury and extensor tendon subluxation (boxer knuckle) [57]. In the hip and groin, dynamic assessment is used to evaluate for snapping hip syndrome [58] and hernias [59]. In the lower extremity and ankle, dynamic imaging is used to diagnose peroneal tendon subluxation [23], Achilles tendon tear [17] Morton neuroma [43], and muscle hernia [60].

CONCLUSION

A number of factors affect utilization of musculoskeletal ultrasound, which indirectly affects MRI utilization. The proliferation of less expensive compact ultrasound units has opened the musculoskeletal ultrasound market beyond radiologists, potentially reducing the number of ultrasound and MRI studies interpreted by radiologists. The use of ultrasound in place of MRI for specific examinations can result in significant cost saving to the health care system but can reduce MRI use. With regard to training, further progress is required to integrate musculoskeletal ultrasound into radiology residency programs similar to musculoskeletal radiology fellowship programs.

Musculoskeletal Imaging * Review

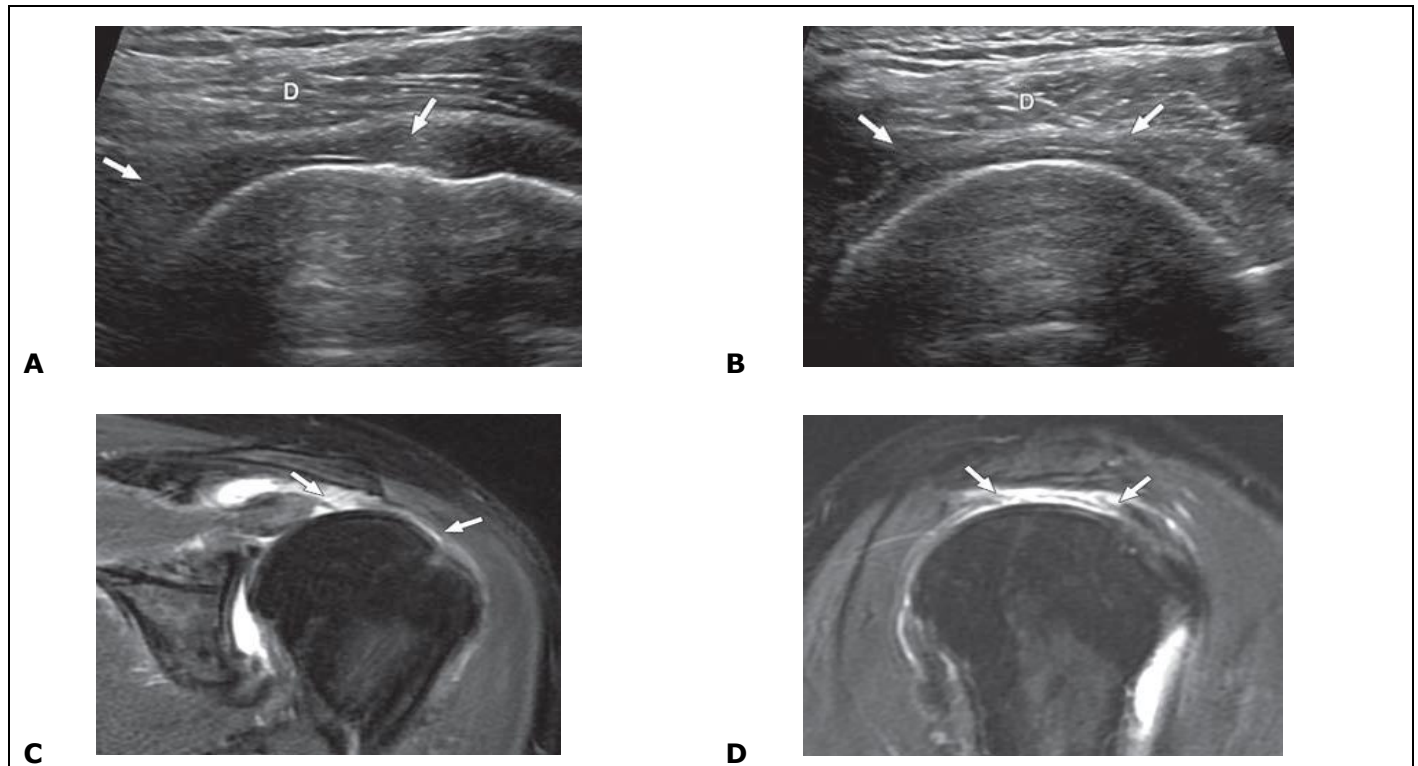


Fig. 3 71-year-old man with full-thickness supraspinatus tear.

A-D, Ultrasound images of supraspinatus tendon (long axis, **A**; short axis, **B**) and coronal oblique (**C**) and sagittal oblique (**D**) fluid-sensitive MR images (TE/TR = 41/3,566) show full-thickness tear of supraspinatus tendon (between arrows). Note loss of normal superior supraspinatus convexity with deltoid muscle (D, **A** and **B**) dipping into torn tendon gap on ultrasound (**A** and **B**).

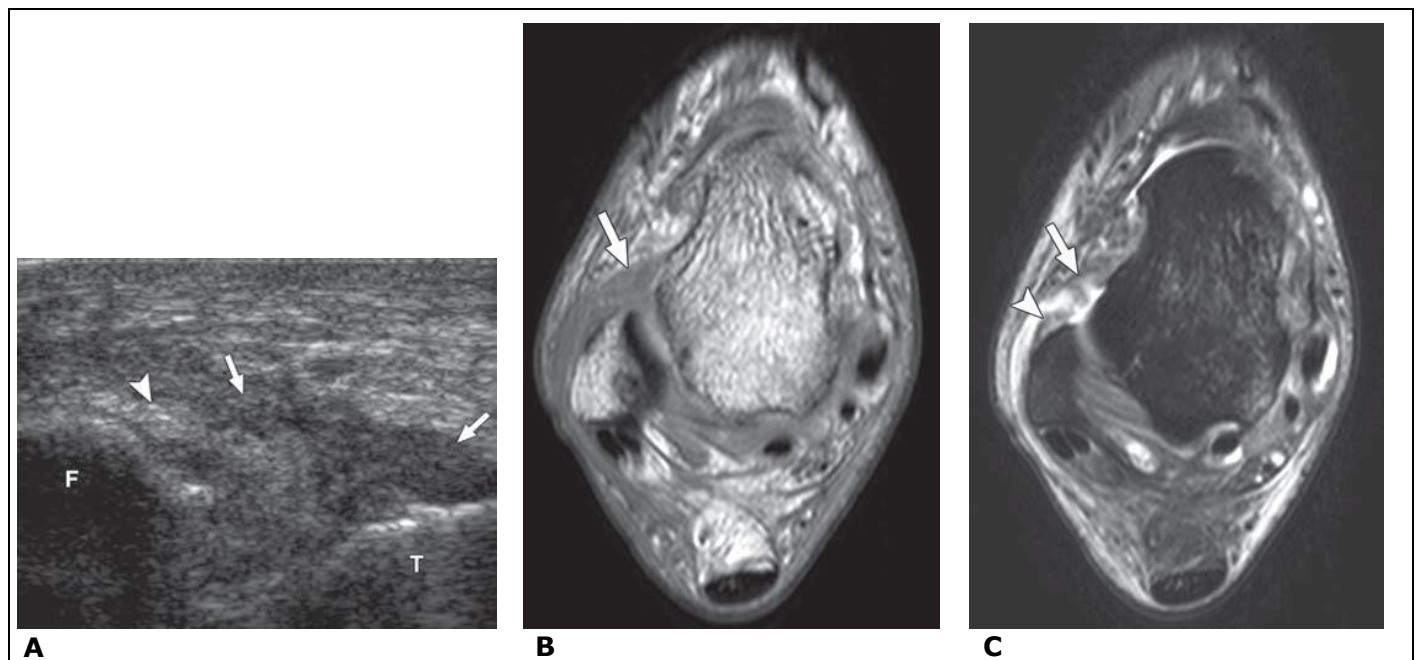
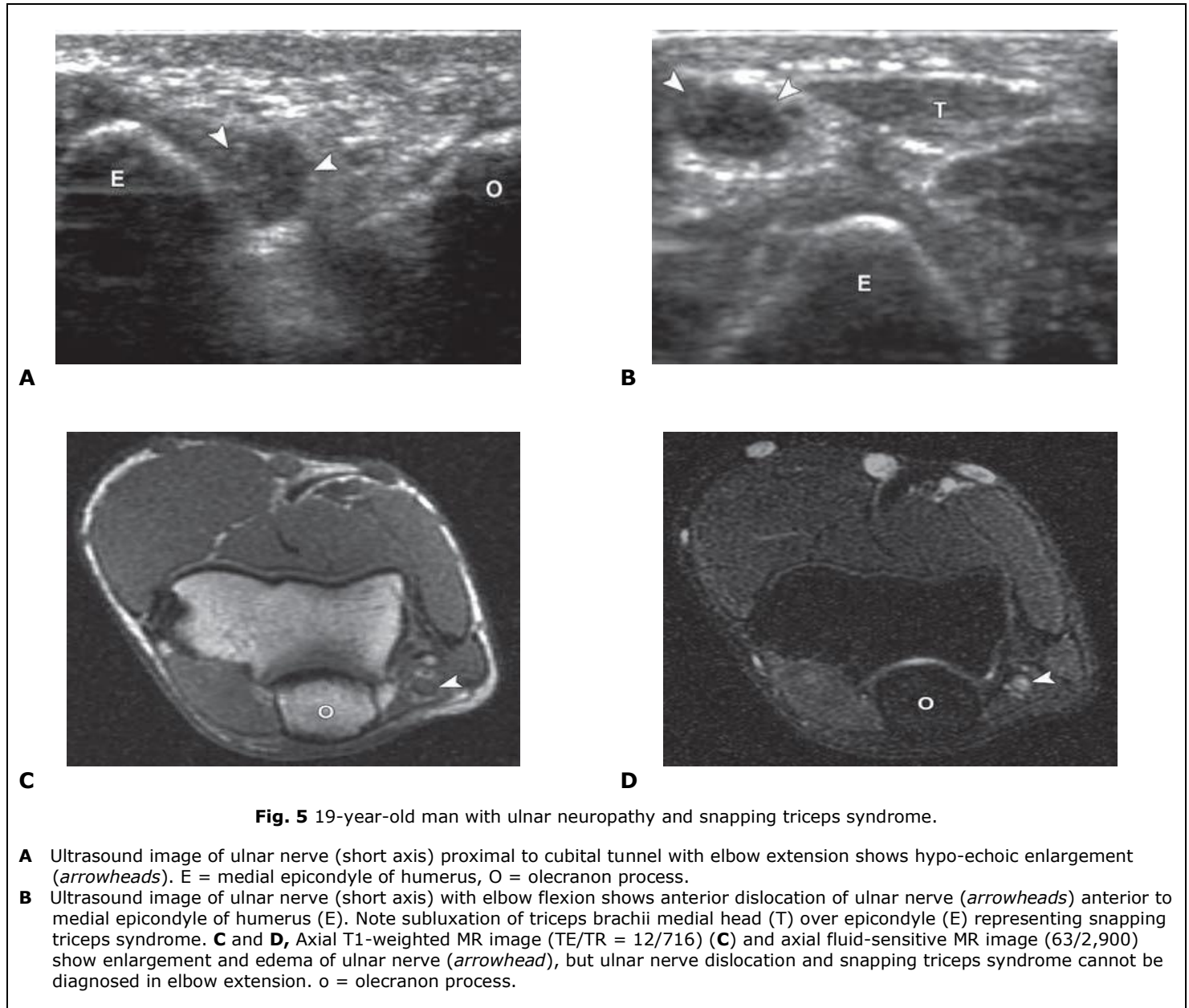


Fig. 4 23-year-old man with anterior talofibular ligament tear.

A, Ultrasound image in transverse plane over anterolateral ankle shows hypo-echoic disruption of anterior talofibular ligament (arrows). Note residual stump of torn ligament (arrowhead) at fibula (F). T = talus. **B** and **C**, Axial T1-weighted MR image (TE/TR = 9/1,123) (**B**) and axial fluid-sensitive MR image (50/3,000) (**C**) show anterior talofibular ligament tear (arrow) and residual stump (arrowhead, B) at fibula.

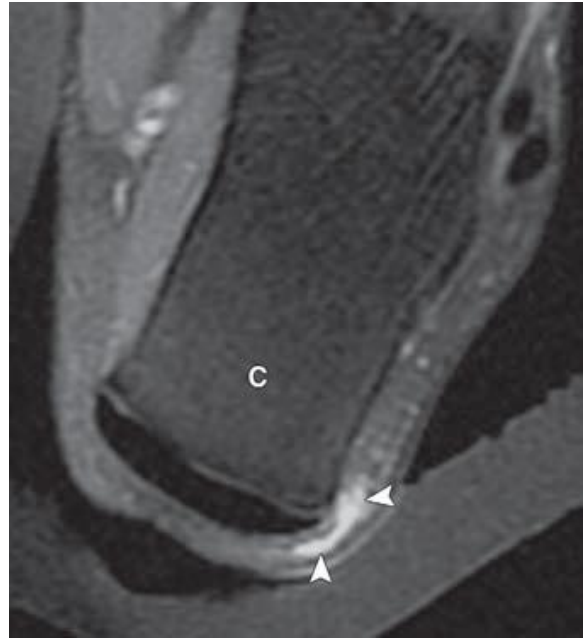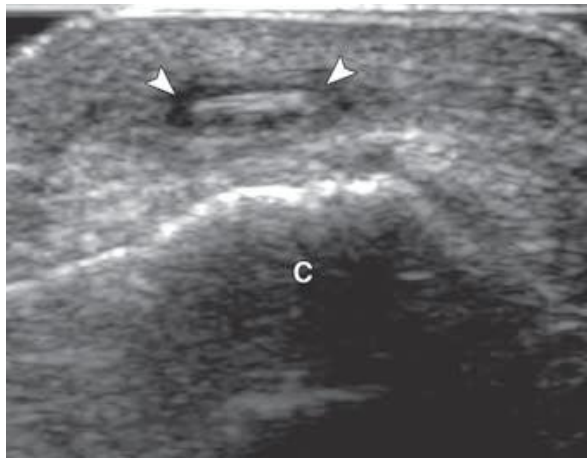Musculoskeletal Imaging * Review



Ultrasound can complement MRI in the evaluation of peripheral nerves, foreign bodies, abnormalities adjacent to hardware, and

conditions that required extremity movement or positioning for diagnosis.

Musculoskeletal Imaging * Review

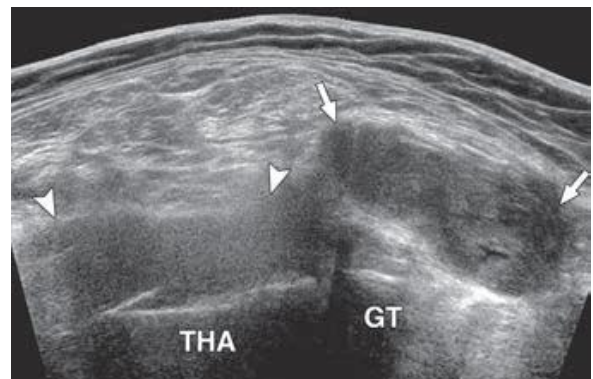
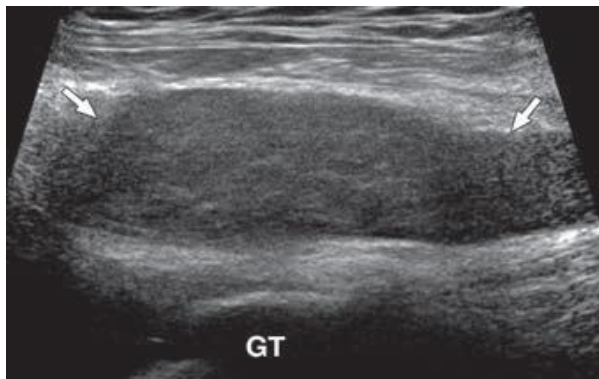


A

B

Fig. 6 47-year-old woman with rose-thorn foreign body.

- A** Ultrasound image shows linear hyper-echoic foreign body (*arrowheads*) with surrounding Hypo-echoic halo of inflammation. c = calcaneus.
B Fluid-sensitive MR image (TE/TR = 50/3,000) shows fluid signal abnormality in soft tissues (*arrowheads*) without showing foreign body. c = calcaneu



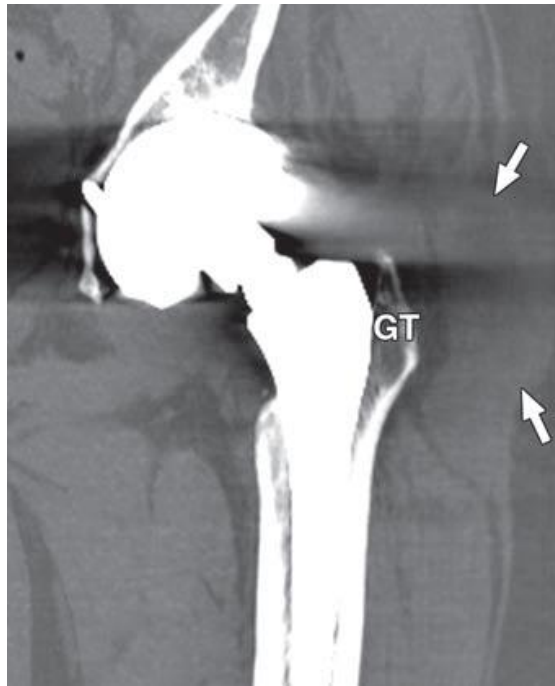
A

B

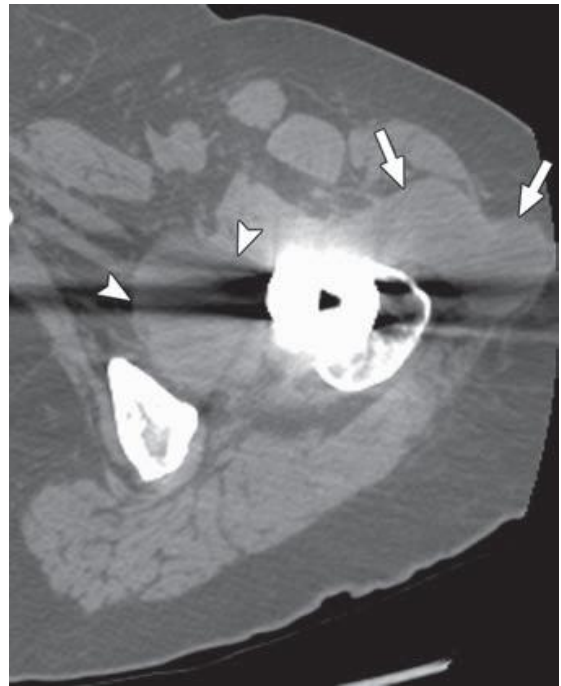
Fig. 7—61-year-old woman with bilateral total hip arthroplasties and left-sided trochanteric bursitis and particle disease.

- A** Ultrasound image lateral to greater trochanter in coronal plane shows hypo-echoic distention of trochanteric bursa (*arrows*). GT = greater trochanter.
B Extended-field-of-view ultrasound image oblique over anterolateral hip shows distended trochanteric bursa (*arrows*) and adjacent hypo-echoic distention of hip joint (*arrowheads*) over femoral neck component of total hip arthroplasty (THA). GT = greater trochanter.

Musculoskeletal Imaging * Review



C

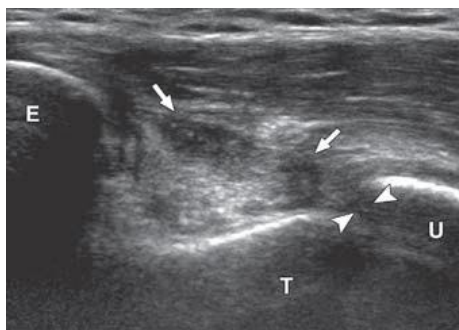

D

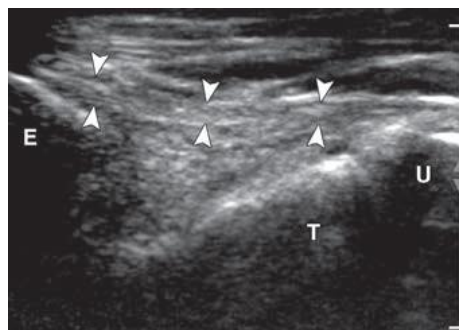
Fig. 7 61-year-old woman with bilateral total hip arthroplasties and left-sided trochanteric bursitis and particle disease

C Multiplanar reformatted unenhanced CT image in coronal plane shows distended trochanteric bursa (*arrows*). GT = greater trochanter.

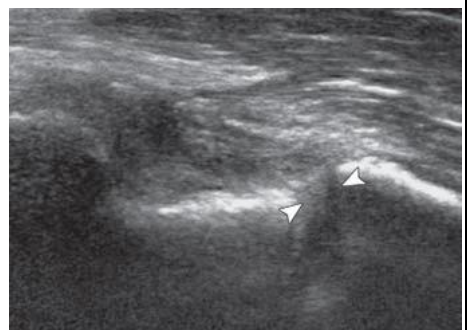D Axial CT image shows distention of trochanteric bursa (*arrows*) and extension of joint process medial to femoral neck (*arrowheads*).



A



B



C

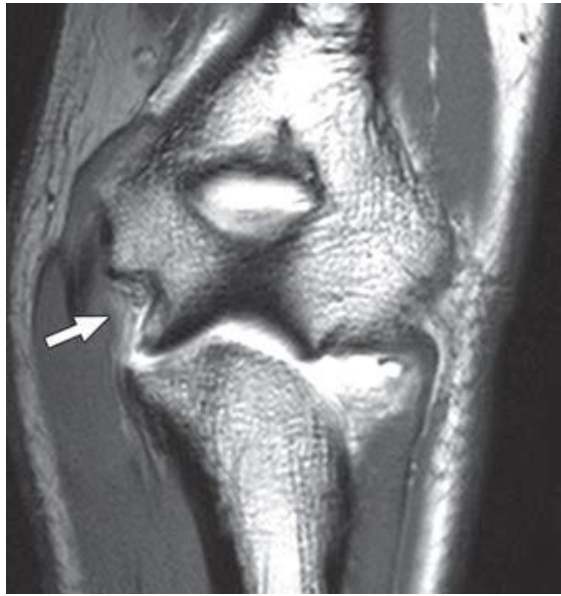Fig. 8 19-year-old man with tear of ulnar collateral ligament, anterior bundle.

A Ultrasound image in coronal plane over medial elbow shows abnormal hypo-echogenicity (*arrows*) in expected location of ulnar collateral ligament, anterior bundle (*arrowheads*). Note wide joint space between trochlea (T) of distal humerus and ulna (U). E = medial epicondyle.

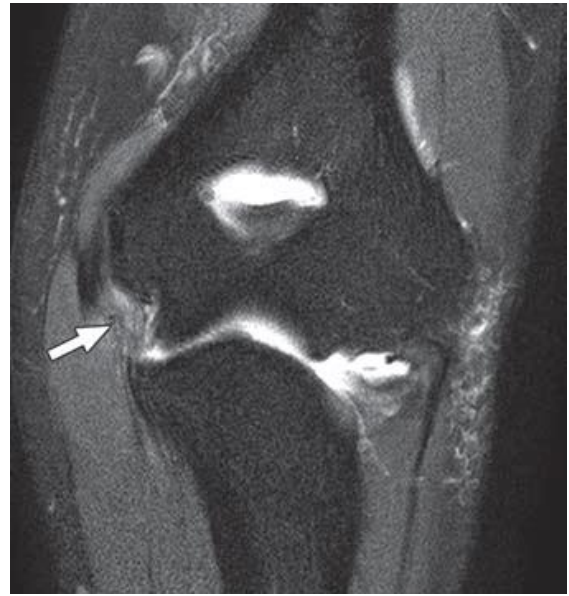B Ultrasound image of contralateral asymptomatic elbow shows normal ulnar collateral ligament, anterior bundle (*arrowheads*), and normal joint space between trochlea (T) and ulna (U). E = medial epicondyle.

C Ultrasound image of symptomatic elbow with valgus stress shows increased widening of joint space (*arrowheads*) when compared with **A**.

Musculoskeletal Imaging * Review



D



E

Fig. 8 19-year-old man with tear of ulnar collateral ligament, anterior bundle

D and **E** T1-weighted MR image (TE/TR = 10/785) (**D**) and intermediate-weighted MR image (40/4,721) with fat saturation (**E**) after intra-articular gadolinium administration show disruption of ulnar collateral ligament, anterior bundle (arrow).

REFERENCES

1. Mayer V. Ultrasonography of the rotator cuff. *J Ultrasound Med* 1985; 4:608, 607
2. Erickson SJ. High-resolution imaging of the musculoskeletal system. *Radiology* 1997; 205:593-618
3. Silvestri E, Martinoli C, Derchi LE, Bertolotto M, Chiaramondia M, Rosenberg I. Echotexture of peripheral nerves: correlation between US and histologic findings and criteria to differentiate tendons. *Radiology* 1995; 197:291-296
4. Martinoli C, Bianchi S, Gandolfo N, Valle M, Simonetti S, Derchi LE. US of nerve entrapments in osteofibrous tunnels of the upper and lower limbs. *Radio Graphics* 2000; 20[spec no]:S199-S213; discussion S213-S217 [Erratum in *RadioGraphics* 2000; 20:1818]
5. Jacobson JA, van Holsbeeck MT. Musculoskeletal ultrasonography. *Orthop Clin North Am* 1998; 29:135-167
6. Martinoli C, Derchi LE, Pastorino C, Bertolotto M, Silvestri E. Analysis of echotexture of tendons with US. *Radiology* 1993; 186:839-843
7. Crass JR, van de Vegte GL, Harkavy LA. Tendon echogenicity: ex vivo study. *Radiology* 1988; 167: 499-501
8. Peetrons P. Ultrasound of muscles. *Eur Radiol* 2002; 12:35-43
9. Peetrons P, Creteur V, Bacq C. Sonography of ankle ligaments. *J Clin Ultrasound* 2004; 32:491-499
10. Teefey SA, Hasan SA, Middleton WD, Patel M, Wright RW, Yamaguchi K. Ultrasonography of the rotator cuff: a comparison of ultrasonographic and arthroscopic findings in one hundred consecutive cases. *J Bone Joint Surg Am* 2000; 82:498-504
11. van Holsbeeck MT, Kolowich PA, Eyler WR, et al. US depiction of partial-thickness tear of the rotator cuff. *Radiology* 1995; 197:443-446
12. Balich SM, Sheley RC, Brown TR, Sauser DD, Quinn SF. MR imaging of the rotator cuff tendon: interobserver agreement and analysis of interpretive errors. *Radiology* 1997; 204:191-194
13. Vlychou M, Dailiana Z, Fotiadou A, Papanagiotou M, Fezoulidis IV, Malizos K. Symptomatic partial rotator cuff tears: diagnostic performance of ultrasound and magnetic resonance imaging with surgical correlation. *Acta Radiol* 2009; 50: 101-105
14. Teefey SA, Rubin DA, Middleton WD, Hildebolt CF, Leibold RA, Yamaguchi K. Detection and quantification of rotator cuff tears: comparison of ultrasonographic, magnetic resonance imaging,

Musculoskeletal Imaging * Review

- and arthroscopic findings in seventy-one consecutive cases. *J Bone Joint Surg Am* 2004; 86:708–716
15. Rockett MS, Waitches G, Sudakoff G, Brage M. Use of ultrasonography versus magnetic resonance imaging for tendon abnormalities around the ankle. *Foot Ankle Int* 1998; 19:604–612
 16. Grant TH, Kelikian AS, Jereb SE, McCarthy RJ. Ultrasound diagnosis of peroneal tendon tears: a surgical correlation. *J Bone Joint Surg Am* 2005; 87:1788–1794
 17. Hartgerink P, Fessell DP, Jacobson JA, van Holsbeeck MT. Full- versus partial-thickness Achilles tendon tears: sonographic accuracy and characterization in 26 cases with surgical correlation. *Radiology* 2001; 220:406–412
 18. Rosenberg ZS, Cheung Y, Jahss MH, Noto AM, Norman A, Leeds NE. Rupture of posterior tibial tendon: CT and MR imaging with surgical correlation. *Radiology* 1988; 169:229–235
 19. Nallamshetty L, Nazarian LN, Schweitzer ME, et al. Evaluation of posterior tibial pathology: comparison of sonography and MR imaging. *Skeletal Radiol* 2005; 34:375–380
 20. Friedrich JM, Schnarkowski P, Rubenacker S, Wallner B. Ultrasonography of capsular morphology in normal and traumatic ankle joints. *J Clin Ultrasound* 1993; 21:179–187
 21. Verhaven EF, Shahabpour M, Handelberg FW, Vaes PH, Opdecam PJ. The accuracy of threedimensional magnetic resonance imaging in the diagnosis of ruptures of the lateral ligaments of the ankle. *Am J Sports Med* 1991; 19:583–587
 22. Chandnani VP, Harper MT, Ficke JR, et al. Chronic ankle instability: evaluation with MR arthrography, MR imaging, and stress radiography. *Radiology* 1994; 192:189–194
 23. Neustadter J, Raikin SM, Nazarian LN. Dynamic sonographic evaluation of peroneal tendon subluxation. *AJR* 2004; 183:985–988
 24. O'Connor PJ, Rankine J, Gibbon WW, Richardson A, Winter F, Miller JH. Interobserver variation in sonography of the painful shoulder. *J Clin Ultrasound* 2005; 33:53–56
 25. Middleton WD, Teefey SA, Yamaguchi K. Sonography of the rotator cuff: analysis of interobserver variability. *AJR* 2004; 183:1465–1468
 26. Le Corroller T, Cohen M, Aswad R, Pauly V, Champsaur P. Sonography of the painful shoulder: role of the operator's experience. *Skeletal Radiol* 2008; 37:979–986
 27. Black J, Cook J, Kiss ZS, Smith M. Intertester reliability of sonography in patellar tendinopathy. *J Ultrasound Med* 2004; 23:671–675
 28. Naredo E, Moller I, Moragues C, et al. Interobserver reliability in musculoskeletal ultrasonography: results from a "Teach the Teachers" rheumatologist course. *Ann Rheum Dis* 2006; 65:14–19
 29. Robertson PL, Schweitzer ME, Mitchell DG, et al. Rotator cuff disorders: interobserver and intraobserver variation in diagnosis with MR imaging. *Radiology* 1995; 194:831–835
 30. WPS Medicare Website. WPS Medicare: Medicare physician fee schedule for Michigan—locality 01. www.wpsmedicare.com/part_b/fees/2009_mi_01.pdf. Updated March 27, 2009. Accessed March 30, 2009
 31. Centers for Medicare & Medicaid Services Website. PFS relative value files. www.cms.hhs.gov/PhysicianFeeSched/PFSRVF/list.asp#TopOfPage. Accessed March 30, 2009
 32. Parker L, Nazarian LN, Carrino JA, et al. Musculoskeletal imaging: Medicare use, costs, and potential for cost substitution. *J Am Coll Radiol* 2008; 5:182–188
 33. Rao S, van Holsbeeck L, Musial JL, et al. A pilot study of comprehensive ultrasound education at the Wayne State University School of Medicine: a pioneer year review. *J Ultrasound Med* 2008; 27:745–749
 34. Berquist TH, Bancroft LW, Kransdorf MJ, Peterson JJ, Anderson MR, Walters RM. Postgraduate musculoskeletal fellowship training in the United States: current trends and future direction. *Skeletal Radiol* 2003; 32:337–342
 35. van Holsbeeck M. Fury over sound. *Arthritis Rheum* 2004; 51:877–880
 36. Hertzberg BS, Kliewer MA, Bowie JD, et al. Physician training requirements in sonography: how many cases are needed for competence? *AJR* 2000; 174:1221–1227
 37. American Institute of Ultrasound in Medicine (AIUM) Website. AIUM practice guideline for the performance of musculoskeletal ultrasound examination. www.aium.org/publications/guidelines/musculoskeletal.pdf. Published October 1, 2007. Accessed March 30, 2009
 38. Jacobson JA. Musculoskeletal sonography and MR imaging: a role for both imaging methods. *Radiol Clin North Am* 1999; 37:713–735
 39. Jacobson JA. Musculoskeletal ultrasound and MRI: which do I choose? *Semin Musculoskelet Radiol* 2005; 9:135–149

Musculoskeletal Imaging * Review

40. Middleton WD, Payne WT, Teefey SA, Hildebolt CF, Rubin DA, Yamaguchi K. Sonography and MRI of the shoulder: comparison of patient satisfaction. *AJR* 2004; 183:1449-1452
41. Nazarian LN. The top 10 reasons musculoskeletal sonography is an important complementary or alternative technique to MRI. *AJR* 2008; 190:1621-1626
42. Jacobson JA, Jebson PJ, Jeffers AW, Fessell DP, Hayes CW. Ulnar nerve dislocation and snapping triceps syndrome: diagnosis with dynamic sonography—report of three cases. *Radiology* 2001; 220:601-605
43. Torriani M, Kattapuram SV. Dynamic sonography of the forefoot: the sonographic Mulder sign. *AJR* 2003; 180:1121-1123
44. Failla JM, van Holsbeeck M, Vanderschueren G. Detection of a 0.5-mm-thick thorn using ultrasound: a case report. *J Hand Surg Am* 1995; 20:456-457
45. Jacobson JA, Powell A, Craig JG, Bouffard JA, van Holsbeeck MT. Wooden foreign bodies in soft tissue: detection at US. *Radiology* 1998; 206:45-48
46. Horton LK, Jacobson JA, Powell A, Fessell DP, Hayes CW. Sonography and radiography of soft tissue foreign bodies. *AJR* 2001; 176:1155-1159
47. Davae KC, Sofka CM, DiCarlo E, Adler RS. Value of power Doppler imaging and the hypoechoic halo in the sonographic detection of foreign bodies: correlation with histopathologic findings. *J Ultrasound Med* 2003; 22:1309-1313; quiz 1314-1316
48. Boyse TD, Fessell DP, Jacobson JA, Lin J, van Holsbeeck MT, Hayes CW. US of soft-tissue foreign bodies and associated complications with surgical correlation. *RadioGraphics* 2001; 21:1251-1256
49. Jacobson JA, Lax MJ. Musculoskeletal sonography of the postoperative orthopedic patient. *Semin Musculoskelet Radiol* 2002; 6:67-77
50. White LM, Buckwalter KA. Technical considerations: CT and MR imaging in the postoperative orthopedic patient. *Semin Musculoskelet Radiol* 2002; 6:5-17
51. Khoury V, Cardinal E, Bureau NJ. Musculoskeletal sonography: a dynamic tool for usual and unusual disorders. *AJR* 2007; 188:203; [web] W63-W73
52. Farin PU, Jaroma H, Harju A, Soimakallio S. Medial displacement of the biceps brachii tendon: evaluation with dynamic sonography during maximal external shoulder rotation. *Radiology* 1995; 195:845-848
53. Bureau NJ, Beauchamp M, Cardinal E, Brassard P. Dynamic sonography evaluation of shoulder impingement syndrome. *AJR* 2006; 187:216-220
54. Peetrons P, Bedard JP. Acromioclavicular joint injury: enhanced technique of examination with dynamic maneuver. *J Clin Ultrasound* 2007; 35: 262-267
55. Miller TT, Adler RS, Friedman L. Sonography of injury of the ulnar collateral ligament of the elbow: initial experience. *Skeletal Radiol* 2004; 33:386-391
56. Nazarian LN, McShane JM, Ciccotti MG, O’Kane PL, Harwood MI. Dynamic US of the anterior band of the ulnar collateral ligament of the elbow in asymptomatic major league baseball pitchers. *Radiology* 2003; 227:149-154
57. Lopez-Ben R, Lee DH, Nicolodi DJ. Boxer knuckle (injury of the extensor hood with extensor tendon subluxation): diagnosis with dynamic US—report of three cases. *Radiology* 2003; 228: 642-646
58. Deslandes M, Guillin R, Cardinal E, Hobden R, Bureau NJ. The snapping iliopsoas tendon: new mechanisms using dynamic sonography. *AJR* 2008; 190:576-581
59. Jamadar DA, Jacobson JA, Morag Y, et al. Sonography of inguinal region hernias. *AJR* 2006; 187: 185-190
60. Beggs I. Sonography of muscle hernias. *AJR* 2003; 180:395-399